

The hands, being composed of many types of tissue, including blood vessels, nerves, skin and skin-related tissues, bones, and muscles/tendons/ligaments, may show changes that reflect a disease that affects other parts of, or even the whole body. These are known as a systemic diseases. The hands may show changes noticed by the patient or his/her hand surgeon even before the disease is detected.

Types of Systemic Diseases

Arthritic Swelling (Figure 1)

Arthritic swelling of the middle joint of a finger is called a Bouchard's node. The swellings at the small finger joints are called Heberden's nodes.

Buerger's Disease (Figure 2)

This is one type of occlusive vascular disease that may affect the fingers (see Vascular Disorders). It is due to an inflammatory disease called vasculitis and is typically associated with smoking. This disease affects the medium and small arteries, so it often affects the fingers and toes. The disease may present as a painful and poorly healing wound or ulcer/gangrene at the fingertip. Involvement of multiple fingers is common. The primary treatment is to avoid smoking. Amputation is sometimes necessary.

Dactylitis (Figure 3)

This case of dactylitis was associated with psoriatic arthritis. In this photo, the swelling extends from the palm to include the ring finger out to the small joint. Stiffness is common. There also may be pain. This swelling may be improved with medicines for the problem causing it.

Mucous Cyst (Figure 4)

This type of cyst is called a mucous cyst. If the skin becomes thin, the cyst may break resulting in drainage of a clear sticky fluid. The resulting break in the skin may allow bacteria to reach the nearby joint, causing a joint or bone infection.

Red Dots (Figure 5)

The small red dots seen above are in the thin part of the skin around the nail. They may also occur in the thicker

pink part. This has been seen in dermatomyositis, systemic lupus, and scleroderma.

Leukonychia (Figure 6)

Leukonychia can be seen with viral infections, intestinal and kidney diseases, poisoning, and medicines. The nail may come loose from the nail bed because of fungal infections or other causes.

Red Streaks (Figure 7)

Red streaks seen in the fingernail area can be due to hemorrhage (bleeding). These are called splinter hemorrhages and have been seen in endocarditis (heart infection), although also reported in psoriasis, and trichinosis.

Psoriasis (Figure 8)

Psoriasis commonly affects the nail and nailbed. Pits in the nail, loosening, blood streaks beneath the nail, and other changes may occur. A psoriasis skin patch is seen in the middle.

"Pincer" Nail (Figure 9)

This "Pincer" nail with an abnormal side-to-side shape curve can be seen at birth or simply due to aging. However, it can also be caused by changes in the bone beneath because of disease (gout in this case).

Pyogenic Granuloma (Figure 10)

This is a fleshy, moist, easily bleeding mass/lump that can affect the fingers, although it has been reported in many other body areas. In the fingers, it is commonly found after trauma to the skin. If there are multiple or recurring lumps, it may be due to the effects of medications or pregnancy. The most effective treatment is surgery to remove the lump, but if it is due to medication, stopping the use of the medication can help.

Terry's Nails (Figure 11)

Fingernails will appear milky white/opaque, except for a small band of pink/red at the end of the nailbed. This appearance was first reported to be associated with liver disease and has also been reported with congestive heart failure, type II diabetes and aging.

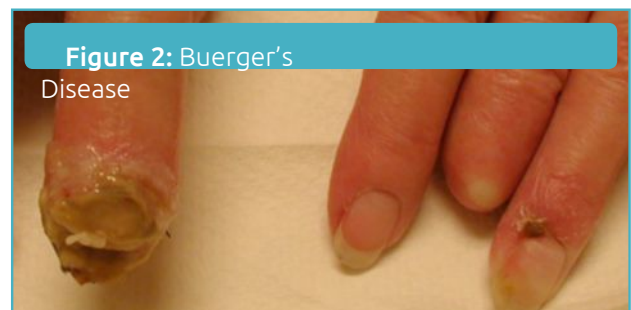
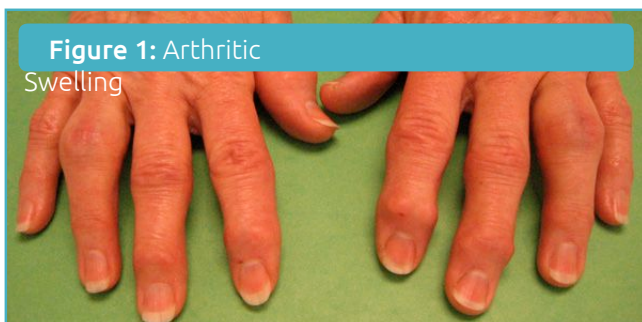

Figure 3: Dactylitis

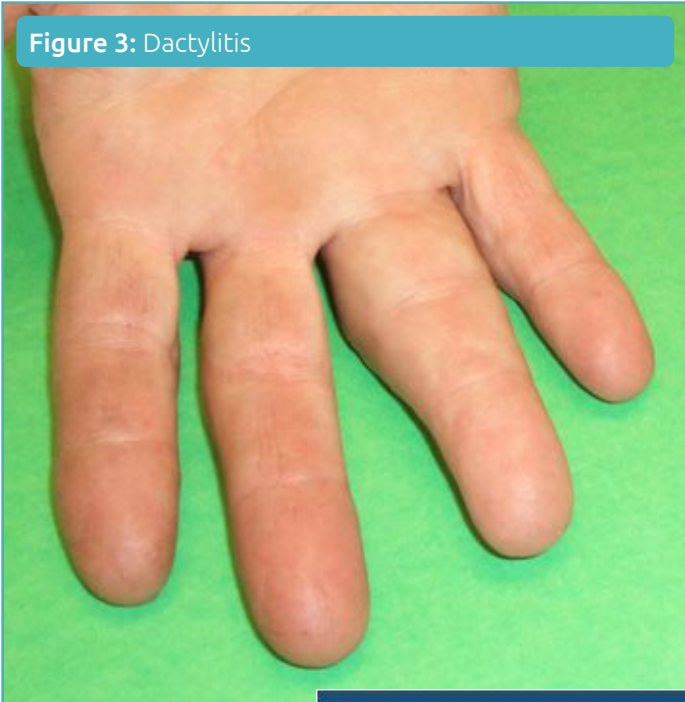


Figure 7: Red Streaks

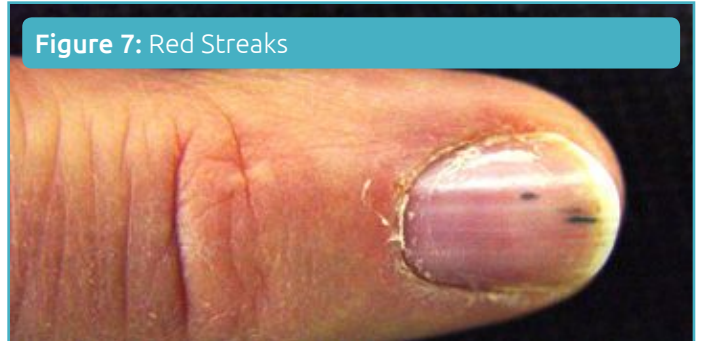


Figure 8: Psoriasis

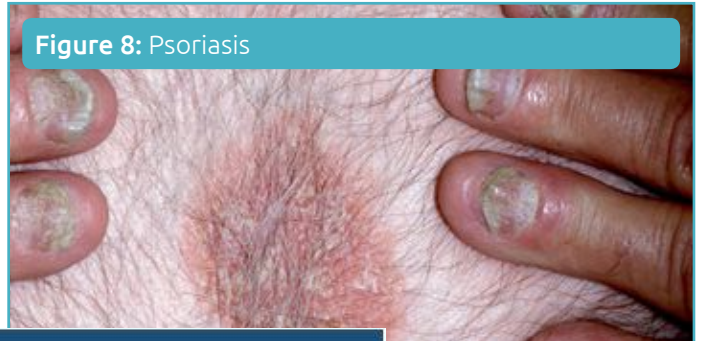
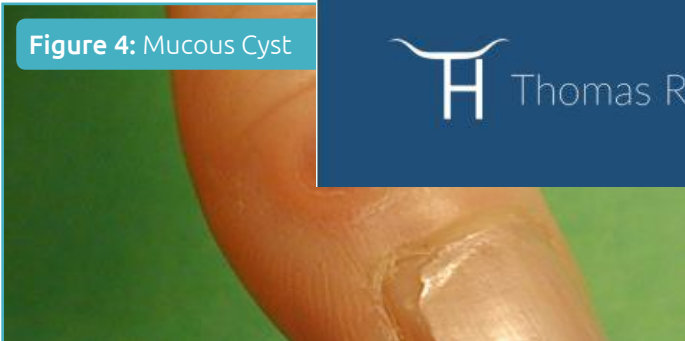

Figure 4: Mucous Cyst



Thomas R. Hunt III, M.D., D.Sc.

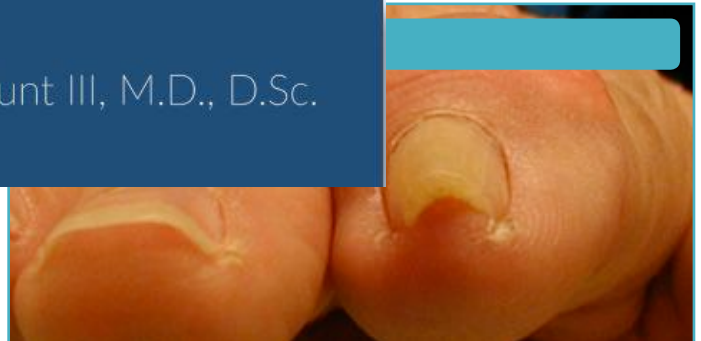

Figure 5: Red Dots

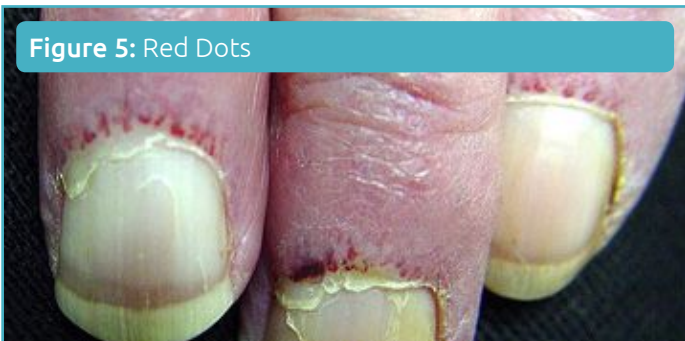

Figure 10: Pyogenic Granuloma

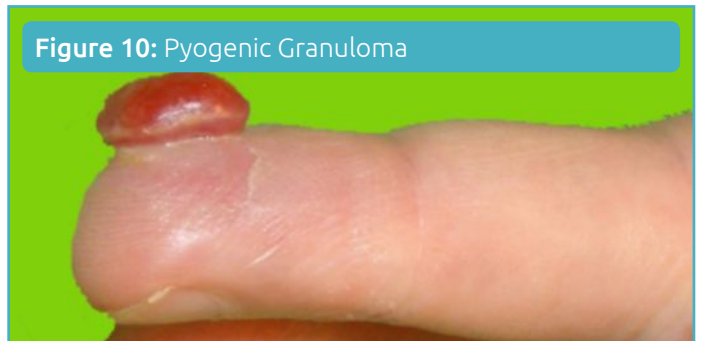

Figure 6: Leukonychia

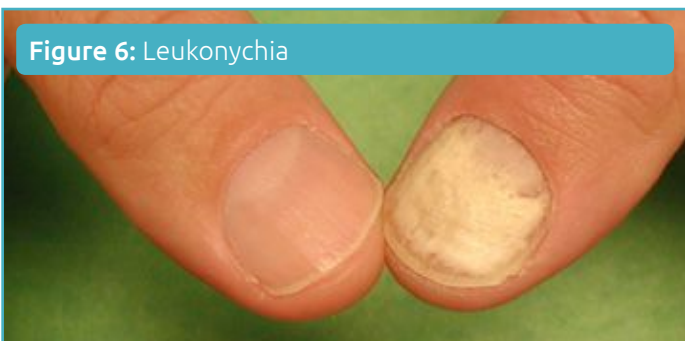

Figure 11: Terry's Nails

